

# **Treatment of chronic type A dissection with a new designed hybridprosthesis**

---

Michael Gorlitzer, Wojciech Wislocki,  
Johann Meinhart and Martin Grabenwöger



ELSEVIER

European Journal of Cardio-thoracic Surgery 31 (2007) 315–317

EUROPEAN JOURNAL OF  
CARDIO-THORACIC  
SURGERY

www.elsevier.com/locate/ejcts

How-to-do-it

## Treatment of chronic aortic type A dissection with a new designed hybridprosthesis

Michael Gortlitz<sup>a,\*</sup>, Wojciech Wislocki<sup>b</sup>, Johann Meinhart<sup>a</sup>,  
Martin Grabenwoger<sup>a</sup>

<sup>a</sup>Department of Cardiovascular Surgery, Hospital Hietzing, Vienna, Austria

<sup>b</sup>Department of Anesthesiology, Hospital Hietzing, Vienna, Austria

Received 29 August 2006; received in revised form 24 October 2006; accepted 7 November 2006; Available online 1 December 2006

### Abstract

This report describes the use of a new combined surgical and endovascular treatment for chronic type A aortic dissection after Cabrol operation. Intraoperative antegrade stenting of the descending aorta combined with distal ascending aorta and aortic arch repair was performed using the E-vita open endoluminal stentgraft. The stentgraft was deployed under direct vision into the true lumen. Postoperative CT scan revealed a partially thrombosed false lumen. This report shows that a combined surgical and endovascular approach of chronic type A aortic dissection in a single stage procedure is a feasible option and extends aortic repair without increase of risk.

© 2007 European Association for Cardio-Thoracic Surgery. Published by Elsevier B.V. All rights reserved.

**Keywords:** Aortic dissection; Stent; Aortic root

### 1. Introduction

We describe a combined approach for treatment of a chronic Stanford type A aortic dissection with replacement of the distal ascending aorta, aortic arch and antegrade stenting of the descending aorta after Cabrol operation and replacement of the proximal ascending aorta in a patient with Marfan's syndrome.

### 2. Technique

A 40 years old female patient with Marfan syndrome underwent replacement of the proximal ascending aorta after acute Stanford type A dissection in April 1993. Within the next year, the patient developed an aneurysm of sinus valsalva and severe aortic regurgitation. Aortic root reconstruction using the Cabrol technique became necessary. Additionally, a 10 mm bypass graft (Hemashield<sup>®</sup>) from ascending aortic prosthesis to the brachiocephalic trunk was performed due to impaired perfusion of the supraaortic vessels caused by the dissection membrane (Fig. 1a). Reoperation because of symptomatic chronic type A aortic

dissection with recurrent chest pain, based on an enlargement of the distal ascending aortic arch and descending aorta with a maximum diameter of 5.9 cm, was indicated (Fig. 2a).

#### 2.1. Endovascular prosthesis

The E-vita open endoluminal stentgraft (Jotec Inc., Hechingen, Germany) consists of a single polytetrafluoroethylene graft encapsulating circumferential Z-shaped nitinol rings along its length and 70 mm Dacron prosthesis at the proximal end. There is no longitudinal support along the length of the graft, as the Z-rings are not linked together to provide exceptional flexibility inside the vessel. We used a 15 cm length self-expandable stent with a diameter of 36 mm; the diameter of the cuff was 34 mm.

Cardiopulmonary bypass was established via the right axillary artery and the right femoral vein. After the target temperature of 25 °C was reached, cardiopulmonary bypass was discontinued. Distal ascending aorta of the aortic arch to the level of the left subclavian artery was opened. True and false lumens of the aorta were identified. Elective bilateral antegrade cerebral protection was established inserting an additional perfusion catheter into the left carotid artery. The stentgraft covered with a thin textile was deployed into the true lumen of the descending aorta. To perform an

\* Corresponding author. Address: Hospital Hietzing, Wolkersbergenstr. 1, A-1130 Vienna, Austria. Tel.: +43 1 80110; fax: +43 1 80110 2729.  
E-mail address: michael.gortlitz@wienkav.at (M. Gortlitz).

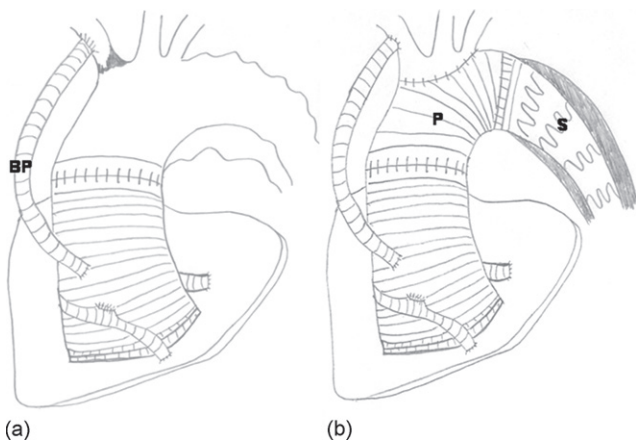


Fig. 1. (a) The graph shows the preoperative dissection of the ascending aorta, aortic arch and descending aorta after Cabrol operation and bypass to the brachiocephalic trunk (BP). (b) Replacement of distal ascending aorta and aortic arch with the Dacron prosthesis (P) reimplanting the supraortic branches and antegrade implantation of the stentgraft (S) into the descending aorta.

anastomosis with the proximal descending aorta, the invaginated Dacron graft is pulled out slightly of the stentgraft and sutured with the dissected descending aorta in a running mattress suture after reinforcing the distal anastomosis with polytetrafluoroethylene (Teflon) felt strips. Then the woven crimped vascular Dacron prosthesis was retracted completely out of the implanted stentgraft and the supraortic branches were reimplanted en bloc, the aortic arch and rest of distal ascending aorta was replaced up to the previously implanted ascending aortic prosthesis (Fig. 1b).

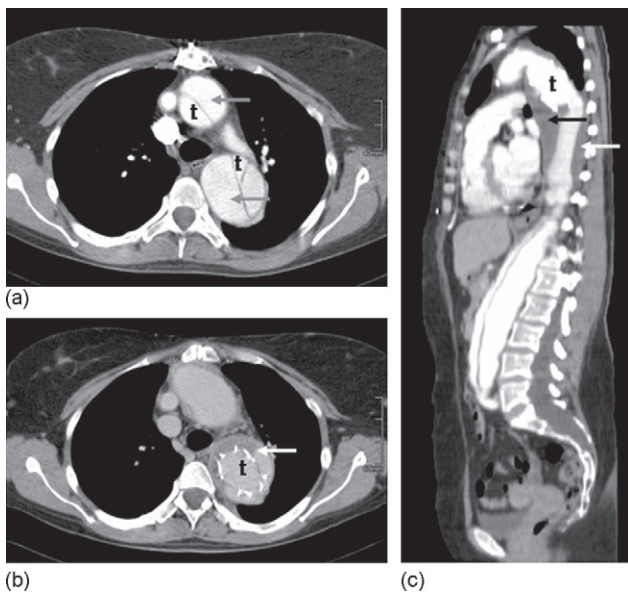


Fig. 2. (a) CT scan shows dissection of the distal ascending and descending aorta. Due to the complex dissection the true (t) and false lumen (arrows) is marked. (b and c) Contrast CT-scans show implantation of the hybridprosthesis. The false lumen around the stented segment of the E-vita prosthesis in the descending aorta is thrombosed partially within 9 days.

### 3. Results

The implantation of the prosthesis was successful in this patient with complex dissection of ascending aorta, aortic arch and descending aorta. Implantation was attempted over an antegrade placed guidewire. The duration of total cardiopulmonary bypass time, hypothermic circulatory arrest time, antegrade selective cerebral and perfusion time were 244, 86 and 69 min, respectively. Deployment of the stented end of the hybridprosthesis required 10 min. Intensive care unit stay was 2 days, the ventilation period 24 h and the hospital stay 14 days. The patient had no neurological dysfunction, the postoperative period was uneventful.

CT scan was performed on postoperative day 9 and revealed a regular position of the stentgraft in the true lumen and beginning partially thrombosed false lumen. Mesenteric and renal arteries were perfused regularly (Fig. 2b and c).

### 4. Discussion

The false lumen distal to the aortic graft remains patent in 70–100% of patients after repair of acute type A aortic dissection by graft replacement of the ascending aorta, reoperation for distal aortic disease is required in 20–30% within the first 5–7 years particularly in patients with Marfan syndrome [1,2].

This report describes the feasibility of combined surgical and endovascular approach of chronic dissection of the aorta with specially designed hybridprosthesis. The risk of a persistent perfused false lumen associated with increased dilatation of the descending aorta and compression of the true lumen followed by impaired distal perfusion can be minimized by stenting the descending aorta together with exclusion of potential entries [3]. At least partial thrombosis of the false lumen at the distal end of the stentgraft can be achieved by this combined procedure. Most importantly, consecutive repair of the distal part of descending aorta especially in patients with Marfan syndrome can be performed without cardiac arrest later if necessary. It facilitates further operations in the thoracoabdominal region because of occlusion of tears and re-entries at the distal descending aorta.

Extensive one-stage or a two-stage approach in complex aortic dissections can be avoided with this one-step procedure avoiding cumulative risks such as the possibility for phrenic or recurrent nerve injury as well as pulmonary complications [4]. Experiences in patients with acute and chronic type A aortic dissections emphasize this procedure [5–7].

In conclusion, the approach of a combined surgical and endovascular approach in the treatment of chronic type A dissection is feasible. At least partial thrombosis of the false lumen can be achieved. Thus, late complications of chronic type B dissection such as increasing aortic diameter and rupture may be reduced. However, further investigations are mandatory to evaluate long-term effectiveness of this new combined treatment modality.

## References

- [1] Detter C, Mair H, Klein HG, Georgescu C, Welz A, Reichart B. Long-term prognosis of surgically-treated aortic aneurysms and dissections in patients with and without Marfan syndrome. *Eur J Cardiothorac Surg* 1998;13: 416–23.
- [2] Estrera AL, Miller CC, Porat EF, Huynh TT, Winnerkvist A, Safi HJ. Staged repair of extensive aortic aneurysms. *Ann Thorac Surg* 2002;74: S1803–5.
- [3] Grabenwoger M, Fleck T, Czerny M, Hutschala D, Ehrlich M, Schoder M, Lammer J, Wolner E. Endovascular stent graft placement in patients with acute thoracic aortic syndromes. *Eur J Cardiothorac Surg* 2003;23:788–93.
- [4] Doss M, Woehleke T, Wood JP, Martens S, Greinecker GW, Moritz A. The clamshell approach for the treatment of extensive thoracic aortic disease. *J Thorac Cardiovasc Surg* 2003;126:814–7.
- [5] Karck M, Chavan A, Khaladj N, Friedrich H, Hagl C, Haverich A. The frozen elephant trunk technique for the treatment of extensive thoracic aortic aneurysms: operative results and follow-up. *Eur J Cardiothorac Surg* 2005;28:286–90.
- [6] Fleck T, Hutschala D, Czerny M, Ehrlich MP, Kasimir MT, Cejna M, Wolner E, Grabenwoger M. Combined surgical and endovascular treatment of acute aortic dissection type A: preliminary results. *Ann Thorac Surg* 2002;74:761–5.
- [7] Kouchoukos NT, Masetti P, Rokkas CK, Murphy SF. Single-stage reoperative repair of chronic type A aortic dissection by means of the arch-first technique. *J Thorac Cardiovasc Surg* 2001;122:578–82.