

**Hybrid antegrade repair of the arch
and descending thoracic aorta
with a new integrated stent-Dacron graft
in acute type A aortic dissection:
a look into the future with new devices**

Carlos-A. Mestres, Claudio Fernández,
Miguel Josa and Jaime Mulet

Case report - Vascular thoracic

Hybrid antegrade repair of the arch and descending thoracic aorta with a new integrated stent-Dacron graft in acute type A aortic dissection: a look into the future with new devices

Carlos-A. Mestres*, Claudio Fernández, Miguel Josa, Jaime Mulet

Department of Cardiovascular Surgery, Hospital Clínico, University of Barcelona, Villarroel 170, 08036 Barcelona, Spain

Received 29 July 2006; received in revised form 15 November 2006; accepted 16 November 2006

Abstract

A young male patient underwent supracoronary replacement of the ascending aorta for acute type A dissection under hypothermic circulatory arrest. After discharge, he was readmitted two weeks later due to severe aortic regurgitation and acute arch redissection. Under a second period of hypothermic circulatory arrest three weeks after the initial operation, radical treatment with aortic valve replacement, replacement of the ascending aorta and arch, together with antegrade deployment of a stent-graft in the true lumen for frozen elephant-trunk technique, were successfully performed. Computed tomography at four weeks showed complete proximal repair and thrombosis of the false lumen. Transesophageal echocardiography at eight weeks confirmed repair. The patient is currently leading an active life. A hybrid approach for complex cases of acute type A dissection with arch involvement can be considered for the future.

© 2007 Published by European Association for Cardio-Thoracic Surgery. All rights reserved.

Keywords: Acute type A aortic dissection; False lumen; Stent-graft; Antegrade deployment

1. Introduction

Acute type A aortic dissection is a surgical challenge. An important issue is the management of the aortic arch which can be complex, especially if individual reattachment of the neck vessels is required. Distal lesions are less amenable through sternotomy. Techniques like the 'elephant trunk' [1] have been used but complexity is still a problem. Stent-graft treatment of the descending thoracic aortic pathology is gaining popularity due to expected lesser morbidity. Some open delivery systems are being evaluated [2, 3]. The combination of both techniques could be an attractive field, provided technology is able to develop integrated stent-grafts for which easy and atraumatic deployment can be guaranteed together with an appropriate graft for arch reconstruction. We present the case of a young patient treated with open stent-grafting for acute type A redissection involving the root, ascending aorta, arch and proximal descending aorta using a new specifically designed integrated stent-Dacron graft for antegrade deployment.

2. Case report

A 36-year-old African agricultural worker with no history of interest was transferred from a community hospital with the clinical and computed tomographic (CT) diagnosis of acute type A aortic dissection on a dilated ascending aorta

(50 mm). Intraoperative transesophageal echocardiography (TEE) showed a left supracoronary tear and trivial aortic regurgitation. Aortic cannulation was directly performed on the distal ascending aorta. The aortic valve looked normal on gross appearance. The right sinus of Valsalva was slightly asymmetrical but not dilated. There was an additional tear in the origin of the innominate artery. Under direct vision, the arch looked normal otherwise as no other findings were detected. Under profound hypothermic circulatory arrest (20 °C, 22 min), supracoronary graft tube replacement of the ascending aorta with a 32 × 10 mm Dacron Intervascular Hemabridge graft with a side branch through which the patient was reperfused upon completion of the distal anastomosis (Intervascular Inc., Montvale, NJ, USA), was performed. Aortic root replacement was not considered in view of the findings. The distal anastomosis was performed on an open basis to appropriately repair the origin of the innominate trunk. TEE after bypass confirmed trivial aortic regurgitation. Following an uneventful postoperative period, he was transferred to his hospital on the fifth postoperative day.

Two weeks later he was transferred again from his community hospital due to CT and echocardiographic findings of massive aortic regurgitation due to prolapse of the non-coronary leaflet and arch redissection. Twenty-one days after the initial operation, intraoperative TEE confirmed massive aortic regurgitation and arch redissection. Cannulation was performed through the Dacron graft. Under profound hypothermic circulatory arrest without cerebral perfusion (20 °C, 105 min), the proximal Dacron graft and

*Corresponding author. Tel.: +34-93-2275749; fax: +34-93-4514898.

E-mail address: cmestres@clinic.ub.es (C.-A. Mestres).

aortic arch were resected. Direct-vision antegrade deployment of an integrated 16×33 mm E-Vita Open stent-Dacron graft in the true lumen of the aorta (Jotec GmbH, Hechingen, Germany) (Fig. 1a,b) was performed. The left subclavian artery was intentionally occluded and ligated. No guidewire through the femoral artery was inserted. The proximal end of the Dacron vascular graft was sutured to the proximal descending thoracic aorta. A 16×8 mm Gore-Tex Stretch bifurcated graft (WL Gore & Associates, Flagstaff, AZ, USA) was anastomosed to the proximal Dacron. A 32×10 mm Dacron Intervascular Hemabridge vascular graft was anastomosed to the previous graft and circulation restarted through its side arm. No additional methods of cerebral protection were attempted in this case even though we use antegrade cerebral perfusion in the surgery of the arch. During reperfusion and rewarming, aortic valve replacement was performed with a 25-mm Carpentier-Edwards Magna pericardial xenograft (Edwards Lifesciences, Irvine, CA, USA). Despite the young age of the patient, the decision of implanting a xenograft was based on the expected lack of compliance for a proper management of oral anticoagulation in such a patient. Intraoperative TEE showed the correct placement of the stent-graft. Due to post-repair coagulation defect and bleeding, the chest was left open.

Two days later, sternal closure was performed. The patient was discharged on the 15th day with no neurological deficit and no left arm claudication. He was seen at our clinic at eight weeks and five months after discharge. CT reconstruction performed with a 64-slice ultrafast CT showed the aortic xenograft, the reconstructed ascending aorta, the bifurcation graft to the neck vessels and the nitinol body of the antegrade stent-graft (Fig. 2a,b). Due to radical treatment of the arch and proximal descending thoracic aorta there is no proximal false lumen and there is thrombosis at this level. The outcome of the left upper limb has been carefully monitored. It is a totally functional left upper limb and, therefore, no attempts for surgical revascularization of the left subclavian artery have been performed.

3. Comment

Type A acute aortic dissection is associated to significant morbidity and mortality. Conventional treatment includes replacement of the ascending aorta and proximal arch with or without valve replacement. Exploration of the arch under circulatory arrest is mandatory. The false lumen

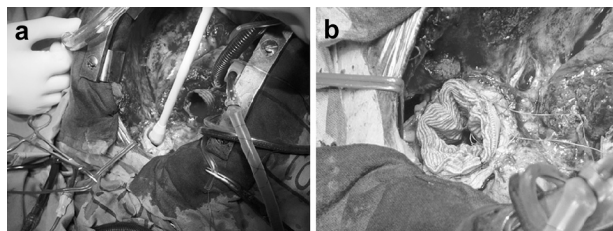


Fig. 1. (a) Antegrade deployment of the stent-graft. The metal bar is introduced in the descending thoracic aorta under direct vision. (b) The proximal end of the stent-graft is in place occluding the left subclavian. The integrated Dacron graft will be sutured to the aortic edge.

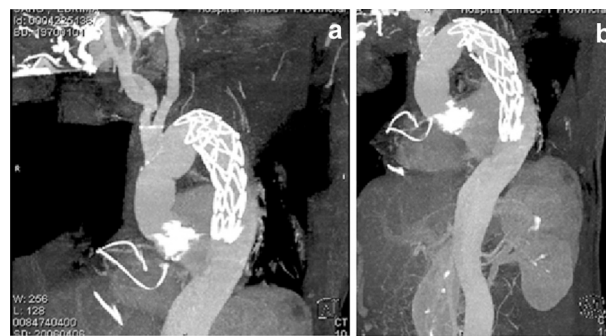

Fig. 2. (a) Subtraction tomography reconstruction shows the completed repair including the absence of arch and proximal false lumen and the reconstructed neck vessels. (b) Subtraction tomography reconstruction shows the completed repair and the aorta distal to the stent-graft.

persists in about 70% of the cases with replaced ascending aorta and in 15–30% when the arch is resected [4]. Persistence of the false lumen may represent an indication for endovascular treatment in the chronic phase as dissection may lead to aneurysmal dilatation. Endovascular therapy facilitates thrombosis of the false lumen [5].

The ‘elephant-trunk’ technique, described by Borst in 1983 [1] facilitates late repair through left thoracotomy or endovascular stent-grafting of the descending thoracic aorta during the follow-up; this technique does not fully prevent dilatation of the false lumen. The use of distally anchored stent-grafts may allow for larger sizes to assist in the prevention of dilatation of the false lumen.

The E-Vita Open stent-graft [6] allows for a hybrid simultaneous repair of the arch and proximal segment of the descending thoracic aorta with exclusion of the false lumen. It has been developed in a similar way as the Chavan-Haverich stent-graft [7] being more flexible than the latter. Antegrade deployment was found to be easy despite the eventual risk of distal perforation. The current model, with the blunt tip and flexible metal holder makes deployment easy and less traumatic.

In this case, the rationale for treating an acute type A redissection was managing the redissected arch. A radical solution was designed with this complex procedure. Acute type A aortic dissection has to be approached with the intention to treat the arch and proximal descending thoracic aorta to eliminate the false lumen and facilitate distal thrombosis. There is not much concern about the chances of developing a descending thoracic aneurysm on a chronic dissection as it has been clearly pointed out by Dobrilovic and Elefteriades [5]. The rationale of caring about late descending aneurysms may not be the most important despite the interesting and attractive follow-up data provided by Uchida et al. in their three-year experience [8].

There have been some attempts for antegrade deployment of stent-grafts during arch exploration in chronic aneurysms or dissections [9, 10]. Acute type A aortic dissection is now being addressed by groups with larger experience. Some questions still need an appropriate answer like the possibility of intraoperative injury of the descending thoracic aorta, the issue of distal embolization or the characteristics of the landing zone that may preclude

deployment or favour poor results. In addition, the issue of the persistence of reentries distal to the stent-graft cannot be underestimated as this is also a frequent finding during the follow-up of patients operated for aortic dissection. The use of specifically designed stent-grafts for antegrade deployment like the Chavan-Haverich [2], the CLATE [3] or the integrated E-Vita Open [6] stent-grafts may open a new type of approach for complex aortic disease.

Acknowledgments

Our colleagues Antonio Garcia-Valentin, Daniel Pereda, Stefano Congiu and Ramon Cartaña have helped the authors in the solution of this and other cases and we extend our deep appreciation to them.

References

- [1] Borst HG, Walterbusch G, Schaps D. Extensive aortic replacement using 'elephant trunk' prosthesis. *Thorac Cardiovasc Surg* 1983;31:37-40.
- [2] Chavan A, Karck M, Hagl C, Winterhalter M, Baus S, Galanski M, Haverich A. Hybrid endograft for one-step treatment of multisegment disease of the thoracic aorta. *J Vasc Interv Radiol* 2005;16:823-829.
- [3] Kubota H, Endo H, Sudo K. New open-stent graft delivery system: 'the CLATE flexible metal graft holder'. *Interact Cardiovasc Thorac Surg* Doi:10.1510/icvts.2006.129882.
- [4] Kazui T, Kimura N, Yamada O, Komatsu S. Total arch graft replacement in patients with acute type A aortic dissection. *Ann Thorac Surg* 1994;58:1462-1468.
- [5] Dobrilovic N, Elefteriades J. Stenting the descending thoracic aorta during repair of Type A dissection: technology looking for an application? *J Thorac Cardiovasc Surg* 2006;131:777-778.
- [6] Jakob H, Tsagakis K, Leyh R, Buck T, Herold U. Development of an integrated stent graft-dacron prosthesis for intended one-stage repair in complex thoracic aortic disease. *Herz* 2005;30:766-768.
- [7] Karck M, Chavan A, Khaladj N, Friedrich H, Hagl C, Haverich A. The frozen elephant trunk technique for the treatment of extensive thoracic aortic aneurysms: operative results and follow-up. *Eur J Cardiothorac Surg* 2005;28:286-190.
- [8] Uchida N, Ishihara H, Shibamura H, Kyo Y, Ozawa M. Midterm results of extensive primary repair of the thoracic aorta by means of total arch replacement with open stent graft placement for an acute type A aortic dissection. *J Thorac Cardiovasc Surg* 2006;131:862-867.
- [9] Kato M, Kuratani T, Kaneko M, Kyo S, Ohnishi K. The results of total arch graft implantation with open stent-graft placement for type A aortic dissection. *J Thorac Cardiovasc Surg* 2002;124:531-540.
- [10] Fleck T, Hutschala D, Czerny M, Ehrlich MP, Kasimir MT, Cejna M, Wolner E, Grabenwoger M. Combined surgical and endovascular treatment of acute aortic dissection type A: preliminary results. *Ann Thorac Surg* 2002;74:761-766.