

Conventional surgical repair and endovascular treatment of acute traumatic aortic rupture

Semih Buz, Burkhard Zipfel, Sead Mulahasanovic,
Miralem Pasic, Yuguo Weng, Roland Hetzer

Conventional surgical repair and endovascular treatment of acute traumatic aortic rupture[☆]

Semih Buz^{*}, Burkhardt Zipfel, Sead Mulahasanovic, Miralem Pasic, Yuguo Weng, Roland Hetzer

Department of Cardiothoracic and Vascular Surgery, Deutsches Herzzentrum Berlin, Berlin, Germany

Received 13 March 2007; received in revised form 28 September 2007; accepted 1 October 2007; Available online 11 December 2007

Abstract

Objective: Endoluminal aortic stent grafting offers a potentially less invasive alternative to open chest surgery, especially in patients with polytrauma. We compare the results of conventional surgical repair and endovascular treatment of traumatic aortic rupture. **Methods:** Retrospectively, 74 patients with acute traumatic aortic rupture were analyzed. Most of the patients had a rupture limited to the isthmus, and severe associated injuries. Thirty-five patients (6 female, 29 male, mean age 36 years) underwent surgical repair. Two patients were operated upon without cardiopulmonary bypass. In 39 patients (5 female, 34 male, mean age 36 years) thoracic endografts were implanted. The delay between trauma and treatment was comparable in the two groups. **Results:** Hospital mortality was 20% (7 of 35 patients) in the surgical group and 7.7% (3 of 39 patients) in the endovascular group. The most common cause of death in the surgical group was brain death in severe traumatic patients. Ten surgical complications occurred in 5 patients: respiratory insufficiency ($n = 3$), pulmonary infection ($n = 2$), recurrent nerve palsy ($n = 2$), repeat thoracotomy ($n = 2$), and compartment syndrome ($n = 1$). No patient in this group had paraplegia. Except for one case, which required conversion to conventional surgery, stent-graft implantation was successful in all cases, without peri-interventional complications or procedure-induced paraplegia. In 9 patients the left subclavian artery was covered with the device. Two patients underwent surgical repair 15 days and 4 months after endografting because of injury of the aortic wall by the stent and development of a spurious aneurysm, respectively. **Conclusions:** In the treatment of traumatic thoracic aortic rupture, the early outcome of patients treated with endovascular stent grafts appears to be better than that with conventional surgical repair. The new technique allows safe and successful repair of this life-threatening injury in the early phase of trauma management. How far this potential benefit is sustained in the long term remains unclear at present.

© 2007 European Association for Cardio-Thoracic Surgery. Published by Elsevier B.V. All rights reserved.

Keywords: Traumatic aortic rupture; Conventional surgery; Endovascular stent graft

1. Introduction

Traumatic rupture of the thoracic aorta is a life-threatening surgical emergency and is often fatal in the first hours after injury. Surviving patients frequently have other associated injuries to various organs such as the head, abdomen, pelvis, or the extremities. Without appropriate treatment, 30% of survivors who reach the hospital die within the first 6 h [1,2]. Despite significant improvements in surgical technique for aortic surgery over the years, the results of early surgical repair are unsatisfactory. Post-operative morbidity remains high and the mortality rate ranges from 15% to 28% [3]. This poor outcome after surgical

repair seems to be related to the other associated injuries that may be present in patients with polytrauma. Standard surgical procedure requires aortic cross-clamping and the use of cardiopulmonary bypass or other arterial shunt techniques for distal perfusion to prevent ischemic, neurological, and visceral complications. However, the necessity of systemic heparinization as required by circulatory assistance increases the risk for fatal hemorrhage, particularly in patients with craniocerebral trauma [4]. Surgical repair with a delay between trauma and treatment, allowing the patient to recover first from other major injuries, has been advocated to improve the outcome of early conventional surgical treatment [5]. However, even in an apparently stable situation, approximately 2–5% of patients experience further rupture within the first week after the trauma [6,7].

Endovascular stent grafting is a less invasive treatment for descending aortic pathologies and may be considered an alternative treatment option to conventional surgical repair. The advantages of endovascular treatment over conventional surgical repair of acute traumatic aortic rupture include the

[☆] Presented at the joint 20th Annual Meeting of the European Association for Cardio-thoracic Surgery and the 14th Annual Meeting of the European Society of Thoracic Surgeons, Stockholm, Sweden, September 10–13, 2006.

^{*} Corresponding author. Address: Department of Cardiothoracic and Vascular Surgery, Deutsches Herzzentrum Berlin, Augustenburger Platz 1, 13353 Berlin, Germany. Tel.: +49 30 4593 1938; fax: +49 30 4593 2100.

E-mail address: buz@dhzb.de (S. Buz).

avoidance of thoracotomy and systemic heparinization. Therefore reduced perioperative morbidity and mortality rates can be expected.

The purpose of this retrospective study was to compare the results of endovascular treatment of traumatic aortic rupture with those of conventional surgical repair in acute settings.

2. Patients and methods

Between 1987 and January 2007, 74 patients with acute traumatic rupture of the aorta underwent treatment at our institution. All patients had sustained a violent blunt chest trauma involving sudden deceleration (road accident or a fall from a great height). Basic diagnostic evaluation of trauma and first-line emergency treatment were performed in all cases in local and regional trauma centers. Patients were referred to our institution when traumatic aortic injury was recognized or suspected; 80% of the patients came from two level 1 trauma centers in Berlin. Table 1 lists the preoperative demographic data and clinical data of all patients. All patients had associated injuries in various organs: at least two additional severe lesions, including lung contusion and/or serial rib fractures with reduced respiratory function, craniocerebral lesions, abdominal visceral lacerations, and multiple extremity or pelvic fractures. To define the severity of trauma in the conventional surgical group and endovascular stent group, an anatomic scoring system, the injury severity score (ISS), from 0 to 75, was used (Table 1) [8]. Thirty-nine patients were admitted to our institution after emergency surgery for life-threatening non-aortic injury such as head injury; abdominal trauma with spleen or liver rupture; or fixation of pelvic, spinal, or extremity fractures.

The diagnosis of traumatic rupture of the aorta was established by spiral computed tomography (CT) at the emergency department (Fig. 2). After admission to our institution, in selected cases, transesophageal echocardiography was also used. Angiography as a pure diagnostic tool

was used in only 14 cases, the last one in 2003. Most patients had the typical rupture of the isthmus ($n = 63$). Six patients had rupture in the aortic arch up to the isthmus, two in the ascending aorta and three in the descending aorta. Four patients had a second rupture in addition to isthmus rupture.

2.1. Therapeutic strategy

The majority of patients had been intubated on admission (26 patients in the surgical group and 21 patients in the endovascular group). We aimed to perform surgical or endovascular repair soon after admission, unless severe associated injuries or complications restricted this policy. In 9 patients treatment was delayed for more than 7 days after trauma due to severe pulmonary contusion in four, severe head injury in three, and infection in two. All patients were monitored on the intensive care unit with continuous monitoring of arterial and central venous pressure, renal function, and other hemodynamic and clinical parameters. Hypertension was prevented with deep sedation and treated, if necessary, with nitrates, calcium-blocking drugs, or nitroprusside.

2.1.1. Surgical group and conventional surgical technique

In our study, 35 patients underwent conventional surgical repair of the traumatic aortic rupture. Thirty-one patients (87.8%) were treated within 7 days; in 19 of them emergency surgery was performed within 48 h after the trauma (in 16 patients within 24 h). Except for two patients who were operated on without cardiopulmonary bypass, in all patients, femorofemoral bypass was established with systemic heparinization. The thoracic aorta was approached through a posterolateral thoracotomy, with an incision in the fourth or fifth left intercostal space. The aorta proximal and distal to the injured segment was dissected and isolated circumferentially and was clamped between the left common carotid artery and the left subclavian artery or distal from the left subclavian artery in 27 patients (82%). A proximal anastomosis to the open

Table 1
Patient population and associated injuries

	Conventional surgical group ^a	Endovascular group ^a
Conventional surgery (1988–2006) ($N = 35$)		
Endovascular stent graft (1999–2006) ($N = 39$)		
Gender (m/f)	29/6	34/5
Age (years/mean/range)	36 (14–73)	36 (15–82)
Delay between trauma and treatment (median/range)	28 h (4 h–219 days)	17 h (3 h–169 days)
ISS (median/range)	34 (9–66)	41 (13–66)
Associated injuries (AIS ≥ 3)		
Head	12	19
Face	7	10
Chest	31	36
Abdomen	17	27
Extremity	22	22
External	2	0

ISS, injury severity score [8]; AIS, abbreviated injury scale [8]: allocated to one of six body regions (head, face, chest, abdomen, extremities [including pelvis], external). Only the highest AIS score in each body region is used (the aortic injury is excluded for the calculation of the chest AIS score). The three most severely injured body regions have their score squared and added together to produce the ISS score (3, severe but not life-threatening injury; 4, life-threatening but survival likely; 5, critical with uncertain survival).

^a p is N.S.

distal arch in circulatory arrest and deep hypothermia was performed in 9 patients (26%). In 8 patients (24%), the aorta was repaired with direct suturing or patch plasty and in 25 patients (76%) a graft was interposed. After weaning from bypass, heparin was reversed with protamine sulphate.

2.1.2. Endovascular stent-graft group and treatment technique

We started thoracic endovascular stent grafting in 1999. After successful experiences with thoracic endovascular treatment in patients with descending aortic aneurysm, we increasingly performed endovascular stent grafting in patients with acute traumatic aortic rupture as a less invasive option for urgent or emergency treatment. In the last 7 years, 39 patients were treated with endovascular stent grafting. Thirty-four patients (87.1%) were treated within 7 days; of these, 29 patients underwent an emergency procedure within 48 h (23 patients within 24 h). We implanted three different commercially available thoracic stent grafts: the Talent (Medtronic Vascular, Santa Rosa, CA, USA) ($n = 27$), E-vita (Jotec, Hechingen, Germany) ($n = 9$), and Relay® (Bolton Medical, Sunrise, FL, USA) ($n = 3$). In all patients, the rupture was located near or distal to the origin of the left subclavian artery. Two patients simultaneously received an additional stent graft for a second rupture, one in the distal thoracic aorta (Relay) (Figs. 1 and 2) and one infrarenal with a bifurcated AneuRX stent graft (Medtronic). The diameter of the stent graft was oversized by 10–20% in relation to the diameter of the native aorta, to achieve a satisfactory tight seal. The endovascular stent grafts used were 28–42 mm in diameter and 100–150 mm in length.

All procedures were performed by the cardiothoracic surgeon in the operating room with the patient under general

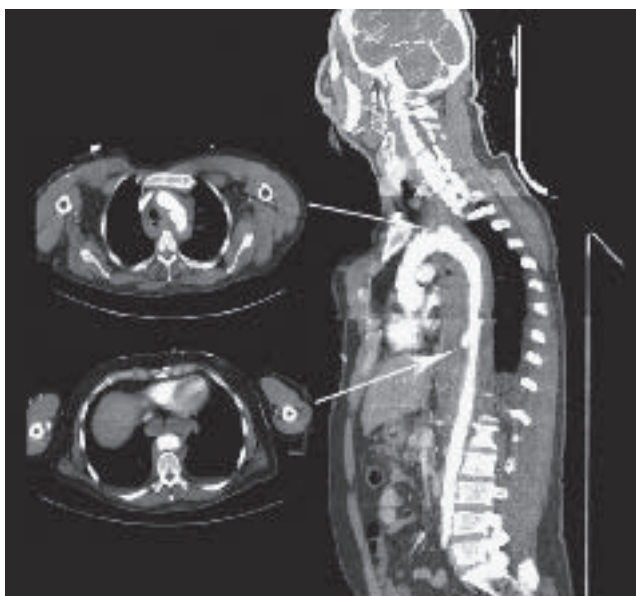

Fig. 1. Double rupture of the thoracic aorta at the isthmus and at the diaphragm in a 46-year-old male patient after a fall from 12 m height, who was transferred in hemodynamically unstable condition. Sagittal CT reconstruction and CT scans on admission to the trauma unit show the contained rupture at the isthmus and disruption at the diaphragm with extensive hematoma in the lower mediastinum.

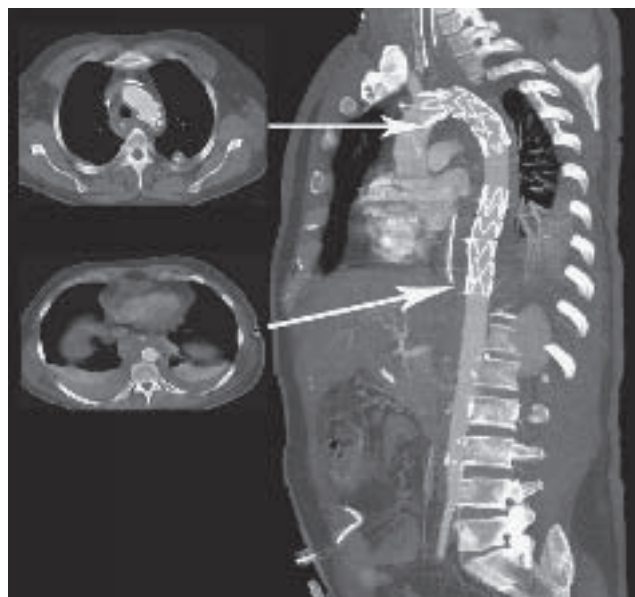


Fig. 2. Same patient as in Fig. 1 after immediate sequential implantation of two Relay® stent grafts. The distal stent graft was implanted first, which resulted in immediate hemodynamic stabilization. Sagittal CT reconstruction on the third postoperative day. The stent graft at the isthmus is oversized by 30% and is bulging into the spot of the rupture. CT scan of stent graft at the diaphragm showing residual hematoma but complete sealing of the lesion.

anesthesia, tracheal intubation, and mechanical ventilation. Patients were placed in the dorsal decubitus position, except one in right lateral position, who was considered at high risk for procedure-induced free rupture. One common femoral artery, at the better accessible side in terms of diameter evaluated in the CT scan and due to associated injuries, was exposed by a small groin incision. In one case a primary retroperitoneal access to the left common iliac artery was chosen, because the access to the groin was blocked by an external fixator for a pelvic fracture. An angiography catheter was introduced by the Seldinger method either through the main access artery or separately from the contralateral groin percutaneously or from the surgically exposed right brachial artery. A maximal dose of 5000 IU of heparin was administered i.v. In cases with fresh associated multiple injuries no heparin was given to avoid the risk of bleeding. A surgical C-arm with subtraction angiography (BV 300®, Philips, Eindhoven, Netherlands) was used for imaging. An initial aortogram was taken from a left, anterior oblique view to visualize the aortic arch anatomy and to determine the best position in which to deploy the stent graft. The angiography catheter was then advanced up to the ascending aorta under fluoroscopic guidance and replaced by a 260-cm long 0.035-inch ultra-stiff guide wire (E-wire® (Jotec, Hechingen, Germany) or Lunderquist® (William Cook Europe, Bjaeverskov, Denmark) or Back-up Meier® (Boston Scientific Scimed, Maple Grove, MN, USA)). The delivery system was positioned at the desired level and the stent graft deployed under fluoroscopic guidance at a mean arterial pressure of less than 70 mmHg to avoid downstream migration of the stent graft during deployment. In 20 patients (51%), the origin of the left subclavian artery (LSA) was covered with the stent graft in order to satisfactorily exclude the lesion. Next, an endovascular balloon was inflated to obtain optimal shape

and sealing of the implanted stent into the normal wall of the aorta. A final aortography was performed to demonstrate stent-graft localization and to ensure that the false aneurysm had been properly excluded. After removal of the introducer delivery system, the femoral artery was closed with a transverse 5-0 prolene (Ethicon, Somerville, NJ, USA) suture.

Postoperatively, the patients were referred back to the trauma centers for further treatment of the associated injuries. Chest X-ray and spiral CT angiography scan were performed before discharge and seen by our team. Follow-up was obtained by office visits, hospital reports, telephone interviews with patients, families and home physicians, and inquiries of local population registries. Two patients, who were transferred back to foreign countries, were lost to follow-up. Actuarial survival was calculated by the Kaplan–Meier method. However, CT scans in the follow-up period were only available in 10 of the 39 patients treated with endovascular stent grafts.

3. Results

3.1. Conventional surgical group

The 30-day mortality was 20% (7 of 35 patients) in patients who underwent surgical repair. The causes of death were severe brain injuries, which deteriorated after the aortic repair in four patients, bleeding in one patient, pulmonary failure in one patient, and low cardiac output syndrome in one patient. Brain death occurred intraoperatively in two patients. The complication rate was also high in this group. In 10 patients (28.5%) significant complications occurred after surgical repair: respiratory insufficiency ($n = 3$), pulmonary infection ($n = 2$), recurrent nerve palsy ($n = 2$), repeat thoracotomy ($n = 2$) because of bleeding and compartment syndrome ($n = 1$). There was no paraplegia associated with the surgical procedure.

The median follow-up for survivors was 6 years (range 0–15.6 years). During follow-up, no patient needed a redo operation. The survival rate at 1, 5, and 10 years was 75% (Fig. 3).

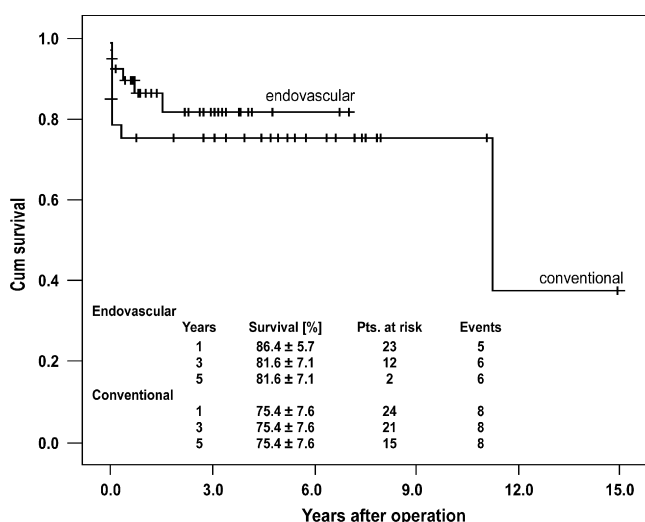


Fig. 3. Cumulative survival curve of both groups.

3.2. Endovascular stent-graft group

In the endovascular group, the 30-day mortality was 7.7% (3 of 39 patients). One of these patients died of severe brain injury, one from pneumonia following severe lung contusion, and one had intraoperative rupture with massive bleeding following stent grafting. In this patient, we performed an emergency conversion to conventional surgery. The removal of the stent and the implantation of an aortic graft were successful under deep hypothermia using cardiopulmonary bypass. However, the patient died of retroperitoneal bleeding after removal of the stent delivery system from the femoral artery. The second patient who needed conversion to conventional surgery was one of the first patients. In this patient, proximal bare spring penetration into the aortic wall occurred, due to a technical fault during implantation, when an attempt was made to readvance the partially opened stent graft in proximal direction. We performed conventional surgery with graft interposition on the 14th postoperative day and the patient could be discharged without complications. One patient had an early proximal type I endoleak, which resolved spontaneously without further intervention.

In all but the case with the intraoperative conversion described above, the endovascular procedure was technically successful (97%). No paraplegia was observed related to the endovascular grafting.

In 5 of 20 patients where the LSA had been covered with the stent graft, a carotid–subclavian bypass was performed: in 4 cases after the endovascular procedure because of symptomatic arm ischemia at exercise or at rest and simultaneously in one 18-year-old man with spinal cord destruction due to a transverse fracture of the third thoracic vertebra in order to prevent ischemic arm problems in wheelchair rehabilitation. Two neurological complications occurred, in which an association with the occlusion of the LSA was suspected. The first case was that of a 42-year-old man after multiple trauma in a motorcycle accident including aortic transection and brain injury with coma at the scene of the accident. Huntington's chorea was previously known in this patient and may have contributed to the accident. The endograft was implanted 3 days after the accident. The postoperative CT scan showed complete exclusion of the aortic rupture and a partially occluded LSA with a mobile thrombus and in the brain multiple contusions, subdural hematoma, and subarachnoid hematoma plus a probably ischemic left cerebellar infarction. The patient did not recover from the brain injury and finally died 5 months after the accident. The second patient, a 57-year-old man, experienced an extremely severe car accident. He had a combination of blunt aortic transection, severe spinal cord and head injuries, and an unstable fracture of the fourth and fifth thoracic vertebra with paraplegia that was evident at the scene of the accident. The thoracic endograft was implanted 8 h after the accident, and the spine was then stabilized. When the patient awoke from anesthesia tetraplegia was noted. CT showed multiple defects and swelling in the brain stem and the left cerebellum. These defects were assumed to be partially due to some grade of ischemia or to the trauma. Neurosurgical decompression was performed, but the patient remained tetraplegic. He finally died 18

months after the accident due to tetraplegia-related pneumonia.

The mean follow-up time was 2.2 years (range 1–7.3). The survival rate was 86.4% at 1 and 81.6% at 5 years (Fig. 3). Three patients died during follow-up from late sequelae of associated injuries. Two are described above. One further patient (39-year-old male) died from graft infection with methicillin-resistant *Staphylococcus aureus* (MRSA) 8 months after the implantation, despite successful explantation of the device and interposition of a conventional Dacron graft. The initial course after multiple trauma had already been complicated by MRSA sepsis. Graft infection with MRSA was found at autopsy.

This was the only device-related complication observed during follow-up. No further endoleak, pseudoaneurysm, migration, or infection was found.

4. Discussion

Acute rupture of the thoracic aorta as the result of blunt chest trauma is a highly lethal condition. Immediate death occurs in up to 85% of cases before the hospital is reached [1,9]. The etiology, patient status at the time of the treatment, and associated injuries are mainly responsible for the poor prognosis of the survivors after the trauma. Despite advances in surgical techniques and management in recent years, immediate surgical repair, including thoracotomy, one-lung ventilation, and use of cardiopulmonary bypass, is associated with a high morbidity and mortality rate. There is general agreement concerning the necessity of surgery in acute traumatic aortic rupture, but the timing of repair is still a matter of controversy. Under discussion are, in particular, the treatment of patients' extrathoracic and craniocerebral injuries or lung contusion and the fear of possible aggravation of intracranial, intra-abdominal, and pelvic bleeding through heparinization during surgery for the aortic rupture. By virtue of these considerations, the concept of delayed elective treatment of the rupture has been developed [7,10]. Based on the experience that those patients reaching the hospital alive are exposed to a constant threat of dying from a second rather than a free rupture during the following hours and days [1], we suggest operation of the rupture directly after its diagnosis, assuming that other actively bleeding injuries, especially of intra-abdominal organs, have been attended to [2]. We have found that free rupture can end the patient's life during even a short period of waiting [11]. Further, in the case of pseudo-coarctation of an untreated contained rupture, paraplegia or severe ischemia of abdominal organs can arise. This concept of instant treatment is also practiced by other authors [12,13]. In-hospital mortality rates increase from 32% on the first day, to 61% within the first week, and 74% after 2 weeks [14,15].

Rousseau et al. [16] have transferred the concept of delayed elective treatment to endovascular repair as well. In this study, however, endovascular repair was performed immediately after trauma or as early as possible. Langanay et al. reported 20% of 50 patients with delayed surgical treatment between 6 and 60 days because of late diagnosis or coexisting life-threatening lesions without further aortic rupture or sudden death [17].

Four different surgical techniques have been described for the repair of an aortic isthmus rupture: clamp and sew, repair with distal perfusion by means of a Gott shunt, left heart bypass, and femorofemoral full cardiopulmonary bypass. The question of which of the four methods should be used for an acute traumatic aortic rupture has been discussed extensively during the last 20 years. In 1994 von Oppel published a meta-analysis of all English-language publications between 1972 and 1992 concerning this question [3]. A total of 985 patients who were operated upon with one of the three methods of distal perfusion had a paraplegia rate of 6.1% compared with 19.2% of the 443 patients who had direct clamping. A summary of studies on this issue published in the later period between 1995 and 1999 revealed similar results [2]. We especially refer to a large prospective multi-center study of the American Association for the Surgery of Trauma (AAST) directed by Fabian, in which 206 patients treated within 30 months were studied [18]. The rate of mortality was similar in the two groups (16.0% vs 17.3%) [2].

The influence of systemic heparinization on mortality and the risk of hemorrhage in such multiple-injured patients, particularly in patients with coexisting brain or pulmonary contusion, remain unclear [3,4,19] because no separate analysis has been made for different forms of distal perfusion.

The recent development of endovascular stent-graft prostheses for the treatment of thoracic aortic disease offers a potentially less invasive and safer alternative to open chest surgery in acute, high-risk surgical patients [20]. Endovascular stent grafting can be performed without aortic clamping and therefore may be applied in a larger number of patients, including hemodynamically unstable cases. The present study represents one of few high-volume single-center experiences in endovascular stent grafting of aortic traumatic rupture [14,19,21–24]. The goal of the endovascular stent grafting is to provide durable exclusion of the lesion while minimizing the morbidity and mortality of the open chest procedure including thoracotomy, one-lung ventilation, cardiopulmonary bypass, significant heparinization, aortic cross-clamping, and spinal cord ischemia. Although neurological complications may occur if the stent graft covers intercostal arteries, this possibility is limited because only few intercostals are involved with a short stent graft and the spinal artery rarely originates from the aortic isthmus.

There are only a few clinical studies reporting comparative analyses of endovascular treatment and conventional surgical repair in traumatic aortic rupture [19,21–23]. In all studies, a clear trend toward improved early outcomes in favor of endovascular treatment with lower mortality, paraplegia, and postoperative complication rate is observed in comparison to open chest surgery. Ott et al. reported a mortality rate of 16% and paraplegia rate of 16% after open repair of traumatic aortic rupture performed without distal perfusion. [22]. This study also demonstrated a clear trend toward an increased rate of complications, such as sepsis, myocardial infarction, acute respiratory distress syndrome, and prolonged ventilation with conventional surgical repair (66%) compared with endovascular treatment (17%).

In our experience, there was no paraplegia in the surgical or endovascular group related to the aortic procedure.

Thirty-day mortality in the endovascular group was 7.7% compared to 21.2% in the conventional surgical group. Due to the small number this difference was not statistically significant. In our series the mortality rate in the conventional surgical group was related to the hemorrhagic complications or rapid deterioration of brain injuries during or after the procedure in four of seven patients who died. In all patients in the conventional surgical group who died, extracorporeal circulation with systemic heparinization was used. Additionally the postoperative complication rate was higher in the surgical group than in the endovascular group (30.3% vs 3%).

In view of these advantages in our practice, endovascular stent grafting has replaced step-by-step conventional surgery as the first-line procedure in managing blunt aortic trauma. Since the introduction of stent-graft therapy in 1999 only 10 patients were operated on conventionally, when the new method was not available at all times in the beginning, the last one in 2004. Currently only patients with rupture proximal to the LSA are excluded from the stent-graft technique; this applied to only one patient since 1999. By means of this new minimally invasive technique the past question of immediate or delayed repair is answered in favor of early repair, which avoids secondary rupture and eases further surgical and intensive care management of associated trauma. It further avoids the above-mentioned disadvantages of distal perfusion, which is necessary for a safe conventional procedure and to reduce paraplegia.

However, some issues remain unsolved. Sizing of the stent grafts is crucial and difficult. In these mainly young patients the aortic diameters are smaller than in the older aneurysm population, for whom the current stent grafts were originally designed. The diameter is variable according to the volume status of the acutely injured patient. Furthermore, the aortic arch is very steep in young patients, which may cause problems with the anchoring of the stent grafts. Collapse of stent grafts has been reported by several authors [25]. We did not experience this kind of complication, probably because we used Dacron/nitinol stent grafts with proximal bare springs, which adapt the proximal end of the stent graft better to the aortic arch. The ideal stent graft for aortic rupture has not yet been found, but the newer designs of this construction seem to be moving in the right direction.

For the same anatomic reasons, in many cases occlusion of the left subclavian artery can be necessary to ensure fixation of the stent graft in the proximal landing zone. If in doubt, the liberal use of this technique is recommended. Ischemic complications of the arm are rare and can be managed easily by extrathoracic carotid–subclavian bypass or transposition in the later phase of trauma management. However, the two neurological complications, which may contribute to the occlusion of the LSA, are a matter of concern. Both occurred in patients with severe spinal cord and brain trauma. Interestingly, no further neurological problems occurred in the patient with spinal cord rupture after we performed carotid–subclavian bypass in the same procedure in view of the practical considerations of further mobilization. This kind of simultaneous procedure may be considered at least in such a combination of injuries.

There seems to be a benefit in the endovascular group in terms of early mortality and complications related to the

aortic procedure. However, secure conclusions cannot be drawn because the two groups are not truly comparative as the two methods were implemented in two different periods and the extent of concomitant injuries seems to be different. There was a trend toward more severe multiple injuries in the stent-graft group, although the difference in the overall injury severity score was not significant. This score, as all others, can only roughly express the severity of trauma, without an individual predictive value [8]. In early and 1-year mortality there seems to be a benefit for the endovascular patients. However, two patients died within 18 months from sequelae of severe cerebrospinal trauma, where the contribution of the endovascular procedure to the aorta remains unclear. One patient died from an MRSA infection of the stent graft, which was clearly acquired in the post-traumatic period, causing MRSA sepsis. The long-term survival is also not comparable due to the different number of patients at risk in the longer follow-up.

Finally, the long-term behavior of the stent-graft implants in mainly young trauma patients remains unclear. So far in all follow-up examinations we saw complete remodeling of the aorta at the rupture site without device-related complications, except in the one case of MRSA graft infection. Whether the early benefit of stent grafting in acute trauma will be sustained needs to be examined in further long-term studies.

Acknowledgments

The authors thank Christine Detschades and Heike Foshitinyo for data collection, Anne Gale for editorial assistance, Julia Stein for calculating the statistics, and Carla Weber and Annette Gaussmann for processing the illustrations.

References

- [1] Parmley LF, Mattingly TW, Manion WC, Jahnke EJ. Nonpenetrating traumatic injury to the aorta. *Circulation* 1958;17:1086–101.
- [2] Hetzer R, Zipfel B. Injuries of the heart and the great thoracic vessels. In: Trentz O, editor, *Tscherne Unfallchirurgie Bd. 2 Kopf und Körperhöhlen*. Berlin-Heidelberg-New York: Springer Verlag; 2000. p. 159–226.
- [3] von Opper UO, Dunne TT, De Groot MK, Zilla P. Traumatic aortic rupture: twenty-year metaanalysis of mortality and risk of paraplegia. *Ann Thorac Surg* 1994;58:585–93.
- [4] Jahromi AS, Kazemi K, Safar HA, Dobay B, Cina CS. Traumatic rupture of the thoracic aorta: cohort study and systemic review. *J Vasc Surg* 2001;34:1029–34.
- [5] Pierangeli A, Turinetto B, Galli R, Caldarella I, Fattori R, Gavelli G. Delayed treatment of isthmus aortic rupture. *Cardiovasc Surg* 2000;8:280–3.
- [6] Holmes JH, Bloch RD, Hall RA, Carter YM, Carmy-Jones RC. Natural history of traumatic aortic rupture of the thoracic aorta managed nonoperatively: a longitudinal analysis. *Ann Thorac Surg* 2002;73:1149–54.
- [7] Pate JW, Fabian TC, Walker W. Traumatic rupture of the aortic isthmus: an emergency? *World J Surg* 1995;19:119–26.
- [8] Baker SP, O'Neill B, Haddon W, Long WB. The Injury Severity Score: a method for describing patients with multiple injuries and evaluating emergency care. *J Trauma* 1974;14:187–96.
- [9] Smith RS, Chang FC. Traumatic rupture of the thoracic aorta: still a lethal injury. *Am J Surg* 1986;152:660–3.
- [10] Maggisano R, Nathens A, Alexandrova NA, Cina C, Boulanger B, McKenzie R, Harrison AW. Traumatic rupture of the thoracic aorta: should one always operate immediately? *Ann Vasc Surg* 1995;9:44–52.

- [11] Zipfel B, Bauer M, Schaffarczyk R, Hetzer R. Operative repair of traumatic aortic rupture with extracorporeal circulation – management and outcome. *Thorac Cardiovasc Surg* 1999;43(Suppl. 1):260–1.
- [12] Hunt JP, Baker CC, Lentz WL, Rutledge RR, Oller DW, Flowe KM, Nayduch DA, Smith C, Clancy TV, Thomason MH, Meredith JW. Thoracic aorta injuries: management and outcome of 144 patients. *J Trauma* 1996;40:547–56.
- [13] Nicolosi AC, Almassi GH, Bousamra M, 2nd, Haasler GB, Olinger GN. Mortality and neurologic morbidity after repair of traumatic aortic disruption. *Ann Thorac Surg* 1996;61:875–8.
- [14] Grabenwoger M, Fleck T, Czerny M, Hutschala D, Ehrlich M, Schoder M, Lammer J, Wolner E. Endovascular stent graft placement in patients with acute thoracic aortic syndromes. *Eur J Cardiothorac Surg* 2003;23:788–93.
- [15] Jamieson WRE, Janusz MT, Gudas VM, Burr LH, Fradet GJ, Henderson C. Traumatic rupture of the thoracic aortic: third decade of experience. *Am J Surg* 2002;183:571–5.
- [16] Rousseau H, Soula P, Perreault P, Bui B, Janne d'Othee B, Massabuau P, Meites G, Concina P, Mazerolles M, Joffre F, Otal P. Delayed treatment of isthmic aortic rupture. *Circulation* 1999;99:498–504.
- [17] Langanay T, Verhoye LP, Corbineau H, Agnino A, Derieux T, Menestret P, Logeais Y, Leguerrier A. Surgical treatment of acute traumatic rupture of the thoracic aorta a timing reappraisal? *Eur J Cardiothorac Surg* 2002;21(2):282–7.
- [18] Fabian TC, Richardson JD, Croce MA, Smith JS, Rodman Jr G, Keaney PA, Flynn W, Ney AL, Cone JB, Luchette FA, Wisner DH, Scholten DJ, Beaver BL, Conn AK, Coscia R, Hoyt DB, Morris JA, Harviel JD, Peitzman AB, Bynoe RP, Diamond DL, Wall M, Gates JD, Asensio JA. Prospective study of blunt aortic injury: multicenter trial of the American Association for the Surgery of Trauma. *J Trauma* 1997;42:374–83.
- [19] Amabile P, Collart F, Gariboldi V, Rollet G, Bartoli LM, Piquet P. Surgical versus endovascular treatment of traumatic thoracic aortic rupture. *J Vasc Surg* 2004;40:873–9.
- [20] Zipfel B, Hammerschmidt R, Krabatsch T, Buz S, Weng Y, Hetzer RJ. Maxwell Chamberlain memorial paper for adult cardiac surgery: stent-grafting of the thoracic aorta by the cardiothoracic surgeon. *Ann Thorac Surg* 2007;83:441–9.
- [21] Rousseau H, Dambrin C, Marcheix B, Richeux L, Mazerolles M, Cron C, Watkinson A, Mugniot A, Soula P, Chabbert V, Canevet G, Roux D, Massabuau P, Meites G, Tran Van T, Otal P. Acute traumatic aortic rupture: a comparison of surgical and stent-graft repair. *J Thorac Cardiovasc Surg* 2005;129:1050–5.
- [22] Ott MC, Stewart TC, Lawlor DK, Gray DK, Forbes TL. Management of blunt thoracic injuries: endovascular stent versus open repair. *J Trauma* 2004;56:565–70.
- [23] Kühne CA, Rucholtz S, Voggenreitter G, Eggebrecht H, Paffrath T, Waydhas C, Nastkolb D. Traumatic aortic injuries in severely injured patients. *Unfallchirurg* 2005;108:279–87.
- [24] Hoornweg LL, Dinkelman MK, Goslings JC, Reekers JA, Verhagen HJM, Verhoeven EL, Schurink GWH, Balm R. Endovascular management of traumatic ruptures of the thoracic aorta: a retrospective multicenter analysis of 28 cases in The Netherlands. *J Vasc Surg* 2006;43(6):1096–102.
- [25] Idu MM, Reekers JA, Balm R, Ponsen KJ, de Mol BA, Legemate DA. Collapse of a stent-graft following treatment of a traumatic thoracic aortic rupture. *J Endovasc Ther* 2005;12(4):503–7.

Appendix A. Conference discussion

Dr D.C. Miller (Stanford, California, USA): Nine of the 31 had the left subclavian covered? Is it correct that 9 of the 31 patients required covering the left subclavian artery covered by the stent graft?

Dr Buz: Yes. In 9 of the 31 patients, the origin of the left subclavian artery was primarily overstented; 5 of them later needed bypass.

Dr Miller: Five needed revascularization?

Dr Buz: Yes.

Dr Miller: Because of arm claudication or posterior fossa cerebral insufficiency?

Dr Buz: The arm symptoms, i.e. arm ischemia at exercise or at rest, were the main indications for revascularization.

Dr Miller: It should be remembered that you cover the left subclavian ostium when you have to in an emergency situation, but you can get burned by a posterior fossa stroke if the left vertebral is large and the right vertebral is hypoplastic or occluded. We use the pre-procedure CTA to assess the vertebral artery anatomy and size to determine whether to revascularize (transposition preferred over carotid–subclavian bypass) the left subclavian system before or during the stent graft. Also remember that the left vertebral artery originates directly from the arch in about 2% of patients – a four-vessel arch – which can be very important.

Dr Buz: In patients with polytrauma, especially with severe head injury, the distinction of neurological complication related to occlusion of the left subclavian artery is difficult. But in this series with 31 patients we have not shown any neurological complication because of LSA occlusion. (Comment: In an oral presentation in Stockholm, we reported 31 patients treated with endovascular stent grafting. After the update of all patients until 2007, the paper reports on 39 patients (endovascular group). In this series we have two patients with neurological complications following LSA occlusion, reported in the paper).

Dr Miller: Yet... As your experience gets larger it will happen. Believe me, this is a tricky and controversial subject.

Dr T. Sundt (Rochester, Minnesota, USA): I may have missed this. In your conventional group, how was the repair performed? Was it performed with left heart bypass? Did you give any heparin? Or did you use full cardiopulmonary bypass? I am concerned about your conclusions, because you seem to have an extraordinarily high CVA rate in your control group of conventional surgery. I'm concerned about how much heparin was administered in the control group.

Dr Buz: We had five patient deaths on intracranial hemorrhage in this group. In all patients who were operated on with cardiopulmonary bypass, systemic heparinization was established.

Dr Sundt: In your control group, how was the operation done? Was full bypass with full heparinization used?

Dr Miller: Two were off-pump, or clamp and sew. What perfusion strategy for spinal cord and lower body protection was used for the others in the conventional surgery control group – left heart bypass, total bypass?

Dr Buz: We had only two patients without cardiopulmonary bypass in the conventional group. Except for two patients who were operated on without cardiopulmonary bypass, in all patients femorofemoral bypass was established. Out of them in 9 patients circulatory arrest and deep hypothermia were performed.

Editorial comment

Management of traumatic aortic rupture: endovascular is the winner

Massive deceleration either horizontal or vertical can cause rupture of the aorta typically at the level of the ligamentum arteriosum (the aortic isthmus) distal to the origin of the left subclavian artery. The moment of inertia displaces the relatively mobile heart together with the aortic arch, while the descending aorta tethered to the spine via

the intercostals pedicles remains fixed. With the vast majority of these injuries incurred through car crashes, nearly 80% of the victims die at scene of the accident as a result of complete aortic transection including the adventitia and attached connective tissue [1]. Approximately 20% reach the hospital alive due to an incomplete disruption of the

tunica intima and media. Tensile strength is provided by the intact adventitia, and the parietal pleura contain the hematoma. However, if left untreated, 5–20 % of these patients are at risk of secondary rupture and intrapleural exsanguination within the first week [2]. In surgically untreated survivors, the natural course of aortic rupture is false aneurysm formation with secondary rupture after months or years.

For decades the treatment of choice has been immediate repair by a left thoracotomy, aortic cross clamping and direct suturing, or prosthetic graft interposition. The outcome has been constantly improved and in particular, the risk of paraplegia resulting from open surgery has been decreased to 2% by the use of partial cardiopulmonary bypass, active distal perfusion, and heparin-bonded circuits. However, mortality remains high with 12–26% due to associated injuries [3,4].

Since the first report of an endovascular treatment of traumatic aortic rupture in 1997 [5], numerous studies including our own experience [6,7] demonstrate a high degree of technical success and low complication rates, although based on a small number of patients. The recent report of Buz and co-workers [8] represents the largest series to date, and corroborates the results of the previous studies. It gives, once again, supporting evidence of an improved early outcome following endovascular repair. The literature gives clear proof of a shift in the management from open surgical to endovascular repair. Although endovascular aneurysm repair was first introduced 16 years ago, and a decade from the first stent graft repair of an acute traumatic rupture, no prospective randomized trial has been performed so far. Endovascular repair has several obvious advantages over open repair:

Increased efficiency: operative trauma load is minimal with a relatively short operating time of 60–90 min.

Improved outcomes: overall early mortality seems to be lower by 3–6%, as well as procedure-related morbidity including pulmonary complications. Heparin administration, even if necessary, is minimized and, therefore, less dangerous in patients with cerebral injuries. The endovascular repair is usually performed in a supine position, which is preferable in the presence of instable spine fractures.

Lower risk: paraplegia as an inherent and tragic complication of open repair, is *not* associated with endovascular repair, as aortic cross clamping is avoided.

Minimized delay: the endovascular approach removes the issue of delaying the repair due to its minimal invasiveness.

While the techniques and technology used in endovascular repair will continue to improve, there are a number of challenges that remain, namely:

Design improvement: there is a demand for smaller device diameters (20 or 22 mm) in these mostly younger patients with a small aorta and a tight aortic arch. Improvements of the devices are likely to mitigate device-related complications such as endoleaks and device collapse. Enhanced flexibility in order to better accom-

modate the steep inner curve of the aortic arch and a covered flap at the proximal end of the device designed to fully appose the inner aortic curve, will enable tight sealing of the aortic tear. A scallop at the outer proximal end of the device could avoid covering the left subclavian artery orifice. However, its covering by the actually available devices is necessary in about one third of the cases, and is rarely associated with impaired perfusion of the extremity. Finally the risk of iliac artery laceration could be decreased by smaller introducer sheaths.

Embolization risk: an inherent risk is the possibility of cerebral embolization resulting from manipulations within the aortic arch, although most of these trauma victims are young and their aortas free of atheroma.

Repair suitability: certain types of lesions are not favorable to an endovascular repair. There is such a circumferential disruption with pseudocoarctation because of the risk of dissection of the aortic arch by endovascular manipulations, or an impending instability of the device because of insufficient anchorage. An aortic disruption with extension into the arch also requires an open repair.

Device durability: the main argument against the endovascular repair, or indeed in favor of a randomized trial, is the unknown outcome in the long term. There are some concerns about device collapse, compression of the left main stem bronchus or aorto-esophageal fistula, however, they seem to be very rare, and mid-term results are encouraging [9,10].

In summary, reduced early mortality and procedure-related morbidity, combined with the absence of paraplegia, are strong arguments in favor of an endovascular repair. Although early results are favorable, long-term outcome is still lacking. Considering the very encouraging experience we have to date, it is difficult to recommend prospective randomized trials. In the challenging management of traumatic rupture of the aorta, the endovascular approach with a record of improved outcomes, is a winning strategy.

References

- [1] Parmley LF, Mattingly TW, Manion WC, Jahnke EJ. Nonpenetrating traumatic injury of the aorta. *Circulation* 1958;XVII:1086–101.
- [2] Pate JW, Fabian TC, Walker W. Traumatic rupture of the aortic isthmus: An emergency? *World J Surg* 1995;19:119–26.
- [3] Cook J, Salerno C, Krishnadasan B, Nichols S, Meissner M, Karmy-Jones R. The effect of changing presentation and management on the outcome of blunt rupture of the thoracic aorta. *J Thorac Cardiovasc Surg* 2006; 131:594–600.
- [4] Jahromi AS, Kazemi K, Safar HA, Doobay B, Cina CS. Traumatic rupture of the thoracic aorta: Cohort study and systematic review. *J Vasc Surg* 2001;34:1029–34.
- [5] Kato N, Dake MD, Miller DC, Semba CP, Mitchell RS, Razavi MK, Kee ST. Traumatic thoracic aortic aneurysm: Treatment with endovascular stent-grafts. *Radiology* 1997;205:657–62.
- [6] Lettinga-van de Poll T, Schurink GWH, De Haan MW, Verbruggen JPAM, Jacobs MJ. Endovascular treatment of traumatic rupture of the thoracic aorta. *Br J Surg* 2007;9:525–33.

- [7] Marty B, Tozzi P, Ruchat P, Huber C, Doenz F, von Segesser LK. An IVUS-based approach to traumatic aortic rupture, with a look at the lesion from inside. *J Endovasc Ther* 2007;14:689–97.
- [8] Buz S, Zipfel B, Mulahasanovic S, Pasic M, Weng Y, Hetzer R. Conventional surgical repair and endovascular treatment of acute traumatic aortic rupture. *Eur J Cardiothorac Surg* 2008;33:143–9.
- [9] Hoornweg LL, Dinkelman MK, Goslings C, Reekers JA, Verhagen HJM, Verhoeven EL, Schurink GWH, Balm R. Endovascular management of traumatic ruptures of the thoracic aorta: A retrospective multi-center analysis of 28 cases in The Netherlands. *J Vasc Surg* 2006;43:1096–102.
- [10] Marcheix B, Dambrin C, Bolduc J-P, Arnaud C, Hollington L, Cron C, Mugniot A, Soula P, Bennaceur M, Chabbert V, Otaï P, Cérène A, Rousseau H. Endovascular repair of traumatic rupture of the aortic isthmus: Midterm results. *J Thorac Cardiovasc Surg* 2006;132:1037–41.

Bettina Marty*
*Department of Cardiovascular Surgery,
University Hospital, Rue du Bugnon 46,
1011 Lausanne, Switzerland*

*Corresponding author. Tel.: +41 26 426 7185;
fax: +41 26 426 7314
E-mail address: martyb@h-fr.ch

Available online 3 December 2007

doi:10.1016/j.ejcts.2007.10.018

